



Jeff Donovan MD PhD FRCPC

Dermatologist, specializing in hair loss

4370 Lorimer Road Suite 334B, Whistler, BC V0N 1B4

Phone: 604.283.1887 Fax: 604.648.9003

Email: whistleroffice@donovanmedical.com Web: www.donovanmedical.com

PATIENT DIRECTED TRICHOSCOPY HOW TO TAKE USEFUL MAGNIFIED PHOTOS USING A USB MICROSCOPE

Dear Patient,

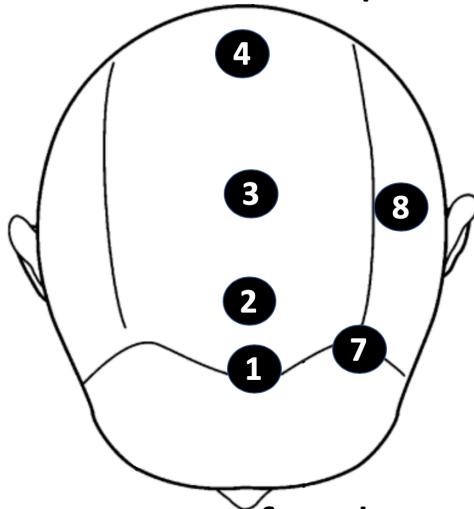
Thank you for taking the time to submit your trichoscopy images to Dr. Donovan. It is greatly appreciated and the goal of you taking these photos is to ultimately provide a better understanding of either your exact diagnosis or your response to treatment (or both).

Dr Donovan reminds all patients of these practical tips:


1. The device you use does not matter all that much. Don't worry too much about the exact device you are using.
2. Please submit clear images that are not blurry.
3. Please indicate where on the scalp these images are taken from. There are 8 standard areas on the scalp that Dr. Donovan recommends photos be taken from. Please submit at least one photo from each of these areas.
4. Please email the photos to whistleroffice@donovanmedical.com and be sure to indicate your name and where on the scalp the images were taken from.
5. Please indicate the date the photos were taken.
6. Here are the 8 areas that photos should be taken from:

- 1 Frontal Hairline
- 2 Frontal Scalp (about 2 inches behind hairline)
- 3 Frontal Scalp (about 3-4 inches behind hairline)
- 4 Frontal Crown (about 5-6 inches behind hairline)
- 5 Back of Crown (upper part of the back of scalp)
- 6 Middle of back of scalp
- 7 Left temple
- 8 Left parietal scalp (2 inches above ear)

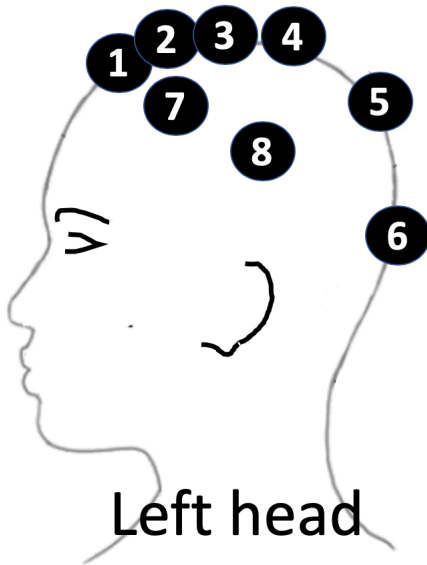
Back of scalp



Front of scalp



Back view of scalp



Left head
side view

- 1** Frontal Hairline
- 2** Frontal Scalp (about 2 inches behind hairline)
- 3** Frontal Scalp (about 3-4 inches behind hairline)
- 4** Frontal Crown (about 5-6 inches behind hairline)
- 5** Back of Crown (upper part of the back of scalp)
- 6** Middle of back of scalp
- 7** Left temple
- 8** Left parietal scalp (2 inches above ear)